

## Entering the Lion's Cage: Correcting RK—A refractive epidemic

Second of two-part column addresses lens-based surgeries in eyes with previous RK

*Gloves Off With Gulani by Arun C. Gulani, MD*

This is the second of a two-part column. In our previous column we discussed addressing the full spectrum of corneal aspects of correcting radial keratotomy (RK) (See “Correcting radial keratotomy: Refractive epidemic of future?” <http://bit.ly/1GMwfYT>). This month, we will “Enter the Lion’s Cage” by discussing lens-based surgeries in eyes with previous RK.

As always, I want to first set the mindset right. Do not get overwhelmed by the appearance of the cornea, number, or pattern of RK cuts in such patients. Approach them with an attitude of perfecting vision through the “excuse/opportunity” of cataract surgery and do not cut corners in bringing these patients to the end zone of vision (“best vision potential,” or BVP)

In case you missed it: NASA calls on ophthalmic companies for space research help

Appreciate the attempt of the RK surgeons, who 20 years ago did the best they could in helping these patients. Let us also not forget that many of these patients did in fact enjoy their life with post RK vision.

Additionally, do not forget that these “Early Adapters” were type A personality then and are Type A today. They still are very well read, well researched, and always wanting and expecting the best possible vision.

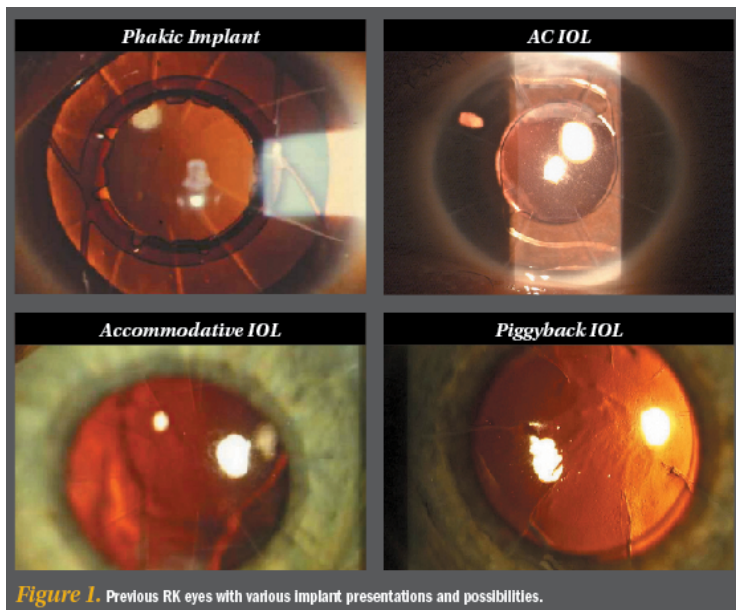


Figure 1. Previous RK eyes with various Implant presentations and possibilities.

Refraction is what starts my thought process with every patient. Just like in my corneal scar cases (See “Decoding corneal scars: Straight to 20/20”; <http://bit.ly/1wh0JK8>), I disregard the RK incisions and focus on the visual capacity of the eye always trying to manipulate the optical elements of the eye in reaching emmetropia/BVP.

So, let’s relieve ourselves of prefabricated myths that premium IOLs don’t work in RK, or that femtosecond laser is difficult to use, or that these eyes are doomed for poor vision. Instead, let’s surprise ourselves and our patients in not only returning back their vision capacity but by further enhancing it with modern technology and dedicated desire to “turn back the clock.”

In this column, I would first like to divide the cases into those of most common presentation, i.e., where cataract and refractive error (most usually hyperopia, astigmatism, and presbyopia) are the most common vision culprits.

Even though these eyes have a cataract, if you concentrate on the refractive outcome, the surgery itself it not as daunting as you may think. Follow our 5S system (see sidebar) to collect the correctable elements of the RK cornea (as we did in our last column) and make a plan to correct the decreased vision resulting from the cataract.<sup>1,2</sup>

Using our 5S system, in most eyes, the corneal scars (cuts), shape, and thickness are all normal, and the site centrally is clear and okay. It’s the Sight that is affected by cataract. Most of these patients present after they’ve become presbyopic, as they’re in their 50s or so. In many cases, they will additionally have hyperopia and astigmatism too.<sup>3</sup> They are frustrated because they have virtually no good vision distance or near. Cataract surgery is our excuse to get back to their good vision.

In this column, I would also like to share my classification system for previous refractive surgery eyes with cataracts to once again outline all factors affected and thence plan a line of attack to get them all in one “Strike.”

### ***Gulani Classification for Previous Refractive Surgery***

Primary Visual factors:

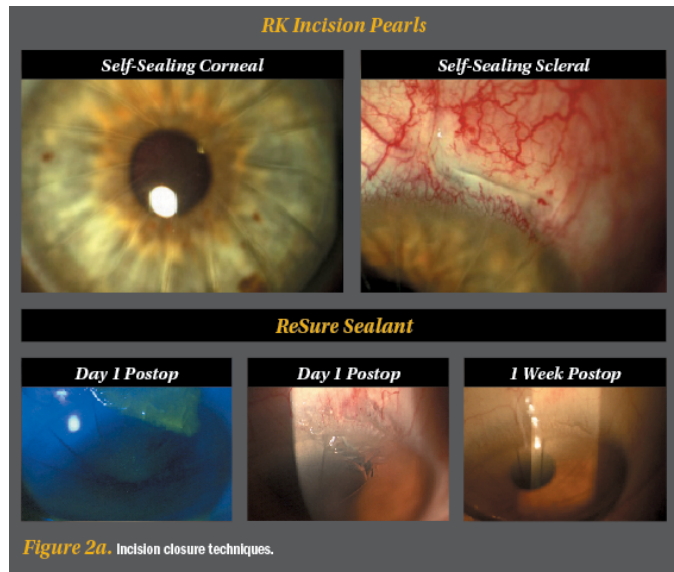
Quantitative:

Decreased visual acuity (Myopia, Hyperopia, Astigmatism)

Qualitative:

Irregular astigmatism

Small Optic Zone

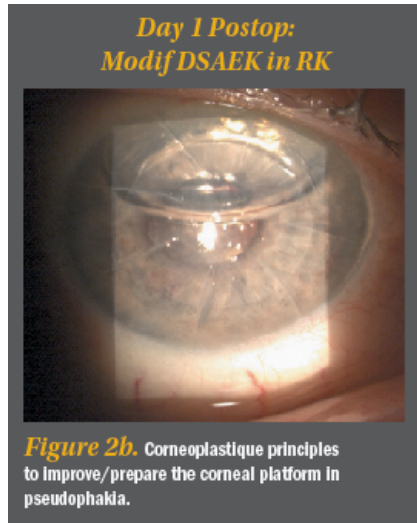


Incisions  
 Secondary (Associated)  
 Visual Factors:  
 Presbyopia  
 Cataracts  
 Corneal Scars  
 Corneal Instability (thin /  
 ectasia / trampoline effect)

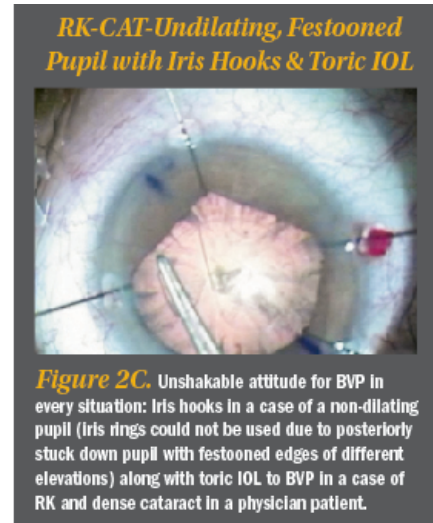
Once the above are listed  
 (primary and secondary  
 factors) and determined,  
 the plan simply unfolds in  
 front of your eyes. The  
 seemingly complex eye  
 now provides an

opportunity to remove the  
 cataract (blurriness) and optically manipulate the interior using specific lens implants to then fine  
 tune/modify or complete our emmetropic quest toward BVP using the cornea as our "Vision  
 Rehabilitative Platform. This is what I call "Refractive Surgery" to the "Rescue" using the most  
 accurate and elegant way to correct vision components with least intervention.

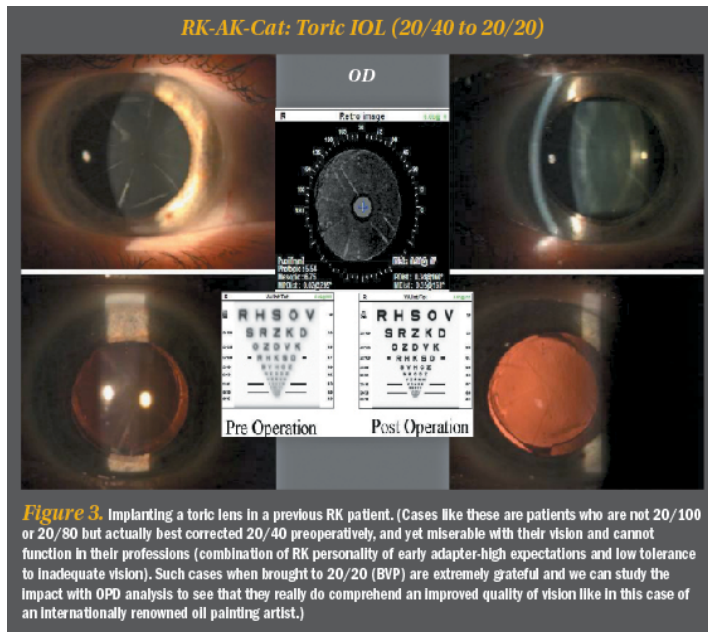
Do not get too anxious about having to perform cataract surgery on a post-RK eye. I would  
 suggest the following pearls:



**Figure 2b.** Corneoplastique principles to improve/prepare the corneal platform in pseudophakia.



**Figure 2c.** Unshakable attitude for BVP in every situation: Iris hooks in a case of a non-dilating pupil (Iris rings could not be used due to posteriorly stuck down pupil with festooned edges of different elevations) along with toric IOL to BVP in a case of RK and dense cataract in a physician patient.



**Figure 3.** Implanting a toric lens in a previous RK patient. (Cases like these are patients who are not 20/100 or 20/80 but actually best corrected 20/40 preoperatively, and yet miserable with their vision and cannot function in their professions (combination of RK personality of early adapter-high expectations and low tolerance to inadequate vision). Such cases when brought to 20/20 (BVP) are extremely grateful and we can study the impact with OPD analysis to see that they really do comprehend an Improved quality of vision like in this case of an internationally renowned oil painting artist.)

1. Select the site of incision (and also your sitting position) based on the axis of astigmatism and available space between two radial incisions. Use clear corneal incisions for patients with under 20 RK incisions, and limbal or scleral tunnel incisions in cases of more than 20 incisions. Sometimes, 16 incisions done irregularly or asymmetrically may also force you to avoid the cornea, so evaluate each case individually.

In the majority of cataract surgery incisions, normal hydration techniques will need to be slightly modified to ensure the previous RK incisions don't leak. I use a 3-point technique where I not only hydrate the medial and lateral side of the main incision but also

centripetally into the lip of the incision.

I have also successfully used and propose the recently FDA approved ReSure Sealant. Of course, good ol' sutures are always a back up. A leaking RK incision is something you do not



want but do resist the urge to use sutures without adequate reason as you will induce astigmatism and healing delays. Most corneal incisions seal and heal very well by correct hydration techniques.

If adjacent RK incisions does come apart, stop surgery, evaluate and suture that incision in a step ladder fashion (minimal sutures with parallel long bites with minimal stress). Resume surgery and your composure without being distracted by these sutures.

2. Gulani Phaco-Feed technique: I use low-flow phacoemulsification or phaco chop techniques to keep the pressure in the eye down as you work. Also keep the phaco hand piece stationary in the incision (so as not to torque or cause stress on the adjacent RK incisions) and feed the cataract with your second hand/instrument into it. In other words manipulate with the second instrument while staying steady with your phaco handpiece.

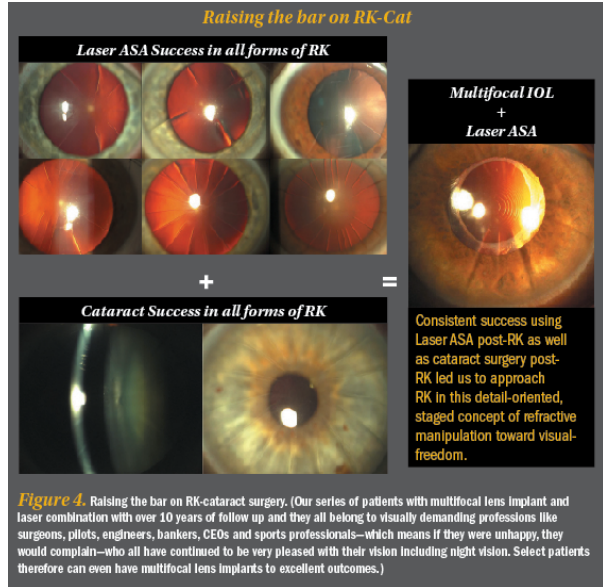


Figure 4. Raising the bar on RK-cataract surgery. (Our series of patients with multifocal lens implant and laser combination with over 10 years of follow up and they all belong to visually demanding professions like surgeons, pilots, engineers, bankers, CEOs and sports professionals—which means if they were unhappy, they would complain—who all have continued to be very pleased with their vision including night vision. Select patients therefore can even have multifocal lens implants to excellent outcomes.)

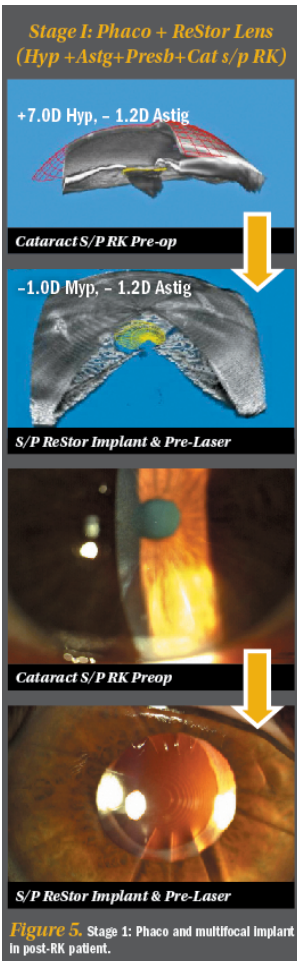


Figure 5. Stage I: Phaco and multifocal implant in post-RK patient.

Femtosecond lasers can be used with no change in protocol or technique to enhance our consistency in capsulorhexis and lens fragmentation which lead the way to successive, next surgical steps in RK cases.4

Always remember that these patients were once myopic in refraction (even though today they may be presenting with hyperopia) and still have the myope's ocular anatomy, so all the risks of cataract surgery in myopia, such as a deep anterior chamber during surgery, and all risks of retinal implications still apply. Do a thorough preoperative and postoperative check.

Visibility sometimes can be hindered if the RK and AK incision pattern reflects and distorts the microscope lights. Establish landmarks like the edge of your capsulorhexis and corneal anatomy so you don't get fooled by light reflexes. A blob of Viscoat on the cornea may help in such cases.5

5. There are numerous sites with formulas and approaches to post RK-IOL calculations and I encourage you to use the one with which you've had the most success. Intraoperative devices like the Wavetec ORA can also be used to further ensure the accuracy of lens powers. Always aim between emmetropia and myopia: That will not only combat any hyperopic shift or refractive fluctuation (and also allow these patients to read for the first time in years) but as we've discussed before (See Decoding corneal scars: Straight to 20/20; <http://bit.ly/1wh0JK8>), myopic laser ASA allows you to increase

optical zone and clear central cornea of irregular astigmatism (both of these additionally help night vision to further enhance patient gratification).

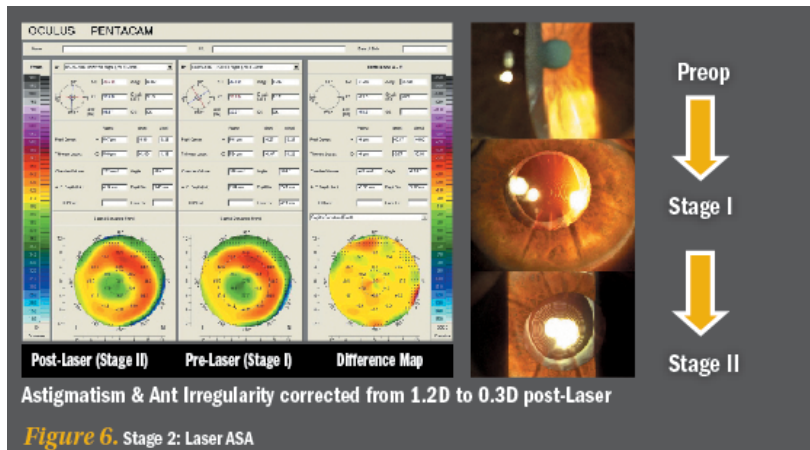
Using the above mentioned pearls, plan for single stage cataract surgery to correct blurry vision (cloudy cataract) and also refractive errors (ie. with Toric IOL if needed) or Two-staged surgery where you result in myopia and then perform Laser ASA as second stage to correct residual refractive error, expand optical zone and clear central corneal irregularities and scars if present.

Additionally, you can use Collagen Cross Linking procedures to further permanize the corneal result you have so laboriously obtained especially if you have worked on the cornea.

Also, build the cornea or repair it in any of the RK cataract cases with no limits and minimal interventions (Corneoplastique).

Having used these concepts I have also used multifocal lens implants successfully in RK cases and we now have a 10 year follow up with these patients who are very appreciative of their vision at distance and near without glasses including night vision

So, in summary, do not let the previous RK incisions deter you from today's premium lens technology, patient expectations or BVP goals.



Do keep in mind to establish realistic expectations and explain lower predictability of outcomes compared to virgin eyes in such patients but also don't forget to still aim for perfection in each of these cases.

Using such mindsets that blur our difficulty levels (RK incisions and associated refractive challenges) and clarify our vision goals (unshakable desire to get to BVP for each patient), we can truly then bring "refractive surgery to the rescue" in such cases and "turn back the clock" on this refractive epidemic of the future.

### Gulani's 5S System

- Sight—Is there potential for vision? If yes, it is our duty to fight for the patient and take them

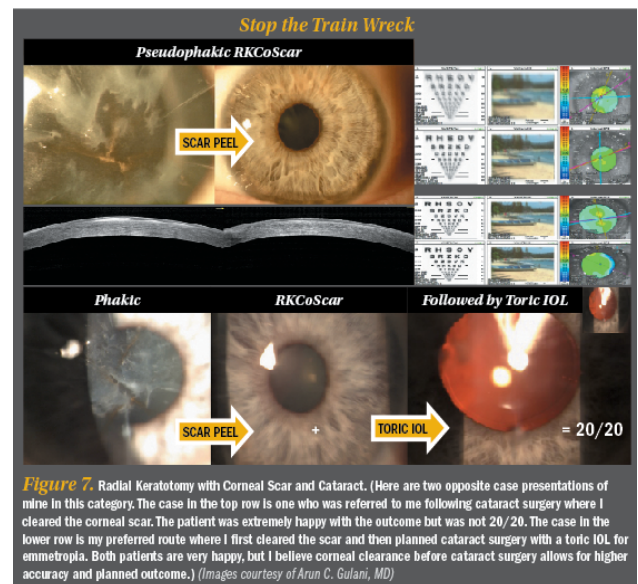


Figure 7. Radial Keratotomy with Corneal Scar and Cataract. (Here are two opposite case presentations of mine in this category. The case in the top row is one who was referred to me following cataract surgery where I cleared the corneal scar. The patient was extremely happy with the outcome but was not 20/20. The case in the lower row is my preferred route where I first cleared the scar and then planned cataract surgery with a toric IOL for emmetropia. Both patients are very happy, but I believe corneal clearance before cataract surgery allows for higher accuracy and planned outcome.) (Images courtesy of Arun C. Gulani, MD)

higher.

- Shape—All corneal refractive surgeries are about shape.
- Scar—Is the cornea clear or does it have an opacity?
- Strength—Is the cornea thicker or thinner than normal?
- Site—Is the center affected or is the periphery? Don't worry about the periphery as long as the patient can see through the center.

### **References**

- Gulani AC. Corneoplastique: Art of Vision Surgery. Ind J Ophthalmol 2014;62:3-11.*
- Gulani AC. Shaping the Future and Reshaping the Past: The Art of Vision Surgery. Chapter 98. In: Copeland and Afshari's Principles and Practice of Cornea. New Delhi, India: Jaypee Brothers Medical Publishers, 2013;2:1252-1273.*
- Donnenfeld E, Gulani AC. Astigmatism correction during cataract surgery. In: Garg H, Alió JL, eds. Femtosecond Laser: Techniques and Technology. 1st ed. Miami; JayPee Highlights Medical Publishers; 2012;21:155-161.*
- Gulani AC. Femtosecond lasers: are they becoming a necessity in Cataract Surgery? Cataract & Refractive Surgery Today. 2013;13:25-26.*
- Gulani, AC. Vision à la carte: Designing vision. Ophthalmology Times. 2013;38(18):31-33.*